



## Advanced Diagnostic Imaging of the Lumbar Spine for Radiological Assessment-An Updated Review

Sattam Mansour Abulkhair<sup>(1)</sup>, Marzog Awwad Alotaibi<sup>(1)</sup>, Ahmad Ali Almahmadi<sup>(2)</sup>, Ghanem Ghazi Menwer Alshammari<sup>(3)</sup>, Abdullah Ahmed Ali Faqihi<sup>(4)</sup>, Anwar Rifadah Abdullah Alanazi<sup>(5)</sup>, Anas Mohammed Mohammed Hakami<sup>(4)</sup>, Hussam Ahmed Hassan Rayyani<sup>(6)</sup>, Ali Ahmed Samhan Alsuhaيمي<sup>(7)</sup>, Abdulaziz Abdullah Masad Almutiri<sup>(7)</sup>, Hassan Salman A Almutairi<sup>(8)</sup>, Omar Mohammed Mufflih Alrashdi<sup>(9)</sup>, Khalid Yousef Ali Alzahrani<sup>(10)</sup>

(1) Al-Fawaz Health Center, Ministry of Health, Saudi Arabia,

(2) Almiqat general hospital, Ministry of Health, Saudi Arabia,

(3) King Khalid general hospital in Hafar al Batin, Saudi Arabia,

(4) King Abdullah hospital - Bisha, Ministry of Health, Saudi Arabia,

(5) Hail General Hospital- Hail, Ministry of Health, Saudi Arabia,

(6) King Fahd central hospital Jizan, Ministry of Health, Saudi Arabia,

(7) Ministry of Health branch in Riyadh, Saudi Arabia,

(8) RABIGH GENERAL HOSPITAL, Ministry of Health, Saudi Arabia,

(9) Hafir Al-Batin Central Hospital, Saudi Arabia,

(10) C1 Riyadh Health Cluster, Ministry of Health, Saudi Arabia

### Abstract

**Background:** Low back pain is a major global health problem and one of the most frequent causes of medical consultation and imaging referral. Its etiology ranges from benign degenerative changes to serious conditions such as infection, trauma, malignancy, and postoperative complications. Selecting the appropriate imaging modality is essential for accurate diagnosis, optimized patient management, and avoidance of unnecessary radiation exposure.

**Aim:** This review aims to provide an updated, comprehensive overview of imaging modalities used in the diagnostic assessment of the lumbar spine, highlighting indications, strengths, limitations, and clinical applications in common and complex lumbar spine pathologies.

**Methods:** A narrative review approach was used to synthesize current evidence and established guidelines, particularly the American College of Radiology (ACR) appropriateness criteria. Imaging modalities discussed include plain radiography, computed tomography (CT), magnetic resonance imaging (MRI), ultrasonography, nuclear medicine techniques, and angiography, with correlation to anatomical, degenerative, infectious, neoplastic, traumatic, and postoperative conditions.

**Results:** Plain radiographs remain a first-line tool for assessing gross structural abnormalities, while CT provides superior evaluation of osseous detail and traumatic injuries. MRI offers unparalleled soft tissue contrast and is the modality of choice for disc disease, spinal canal masses, infection, malignancy, and postoperative complications. Nuclear medicine and angiographic studies serve complementary roles in functional assessment and vascular pathology, respectively.

**Conclusion:** An evidence-based, patient-centered imaging approach tailored to clinical presentation and suspected pathology is critical in lumbar spine evaluation. Integration of multimodal imaging enhances diagnostic accuracy and improves clinical outcomes.

**Keywords:** Lumbar spine, low back pain, MRI, CT, spinal imaging, radiology.

### Introduction

Low back pain represents a prevalent clinical concern and constitutes the second most frequent reason for patient consultations in the United States [1]. Between 2000 and 2016, low back pain accounted for approximately 4.4% of all emergency department visits [2]. The lifetime prevalence of this condition ranges between 70% and 85%, highlighting its widespread impact on population health [3]. Etiologies of low back pain are heterogeneous,

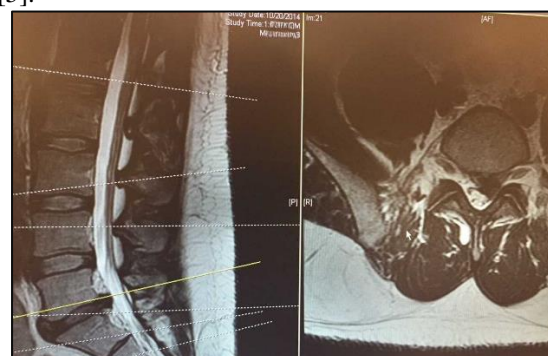encompassing benign causes such as muscle strain and disc protrusion, as well as serious pathologies including discitis, osteomyelitis, and malignant lesions. Accurate diagnosis often relies on imaging, with modality selection tailored to the clinical scenario. Conventional radiography, computed tomography (CT), and magnetic resonance imaging (MRI) remain the principal techniques, while ultrasound (US) and nuclear medicine studies are employed selectively. The American College of

Radiology (ACR) provides appropriateness criteria to guide imaging decisions, emphasizing that routine imaging is unnecessary for uncomplicated low back pain unless symptoms persist beyond six weeks [4]. Imaging becomes imperative in the presence of red flag features, such as cauda equina syndrome, suspected infection, malignancy, or vertebral fracture. Cauda equina syndrome manifests through neurological deficits including saddle anesthesia and bowel or bladder incontinence. Clinical suspicion for infection arises in patients presenting with fever, low back pain, immunosuppression, or a history of substance misuse. Initial evaluation often begins with plain radiographs; however, modality selection must consider patient stability, acuity, contraindications, and the suspected underlying pathology. In cases of suspected infection or malignancy, contrast-enhanced imaging is strongly recommended to optimize diagnostic yield. The ACR appropriateness criteria serve as a critical decision-making tool, providing evidence-based guidance for modality selection in diverse clinical contexts. CT imaging is preferred when evaluating suspected vertebral fractures due to its high resolution for osseous structures. MRI offers superior soft tissue characterization, rendering it the modality of choice for assessing spinal cord compression, neoplasms, and metastatic disease. Additionally, MRI is indicated for patients considered for spinal augmentation procedures, providing detailed anatomical visualization to guide intervention. Overall, the selection of imaging modality in low back pain must integrate clinical presentation, underlying pathology suspicion, patient comorbidities, and evidence-based guidelines to ensure accurate diagnosis and effective management [1][2][3][4].

### Anatomy

The lumbar spine comprises five distinct vertebral bodies, each contributing to the structural stability and flexibility of the lower spine. Anatomical variations are common, yet recognizing transitional vertebrae at the lumbosacral junction is critical for clinical and surgical planning. These variations include lumbarization of S1, in which the first sacral segment assumes characteristics of a lumbar vertebra, and sacralization of L5, where the fifth lumbar vertebra partially fuses with the sacrum. Identification of the L5 vertebral body is aided by the iliolumbar ligament, which originates from the transverse process of L5 and attaches to the iliac crest, as well as by the relative size of the vertebral body. The spinal cord typically terminates at the L1-L2 vertebral level, with the nerve roots extending caudally forming the cauda equina. This structure consists of free-floating nerve roots within the central canal that exit at their respective lumbosacral levels. Accurate recognition of these features is essential for interventions such as lumbar puncture, spinal surgery, and targeted nerve root injections [5]. Intervertebral discs of the lumbar spine consist of the

central gelatinous nucleus pulposus and the surrounding fibrocartilaginous annulus fibrosus. Standardized terminology for disc pathology is guided by recommendations from the American Society for Spine Radiology, the American Society for Neuroradiology, and the North American Spine Society. The most recent update, Lumbar Disc Nomenclature version 2.0, published in 2014, refined definitions established in the original 2001 version [5]. Disc herniation occurs when disc material extends beyond the margins of the intervertebral disc space, often impinging on adjacent neural structures. Posterior disc herniations are a frequent source of nerve compression and symptomatic radiculopathy [5].



**Fig. 1:** Magnetic Resonance Imaging, Lumbar. The image shows T2-weighted sagittal and axial views of lumbar MRI.

Classification of disc herniations is based on the extent and morphology of disc involvement. A protrusion involves less than 25% of the disc circumference, whereas a bulge encompasses more than 25%. When the anteroposterior length of a protrusion exceeds its width, the lesion is termed an extrusion. In cases where the extruded disc fragment loses continuity with the parent disc, the condition is classified as a sequestered disc. Axial imaging further categorizes disc herniations by their spatial relationship to the spinal canal and neural foramina. Central protrusions occupy the midline, paracentral protrusions are situated adjacent to the central canal, foraminal protrusions extend into the intervertebral foramina, and extraforaminal protrusions lie lateral to the foramina. The location of a disc herniation directly influences which nerve roots are affected. Paracentral protrusions typically impinge on the traversing nerve root at the level below the disc, whereas foraminal protrusions compress the exiting nerve root at the same vertebral level [4][5]. Understanding the anatomical and pathological nuances of the lumbar spine is vital for accurate diagnosis, treatment planning, and surgical intervention. Imaging modalities, including MRI and CT, provide detailed visualization of vertebral alignment, disc morphology, and nerve root involvement, facilitating precise identification of pathology. This knowledge underpins clinical decision-making for procedures ranging from

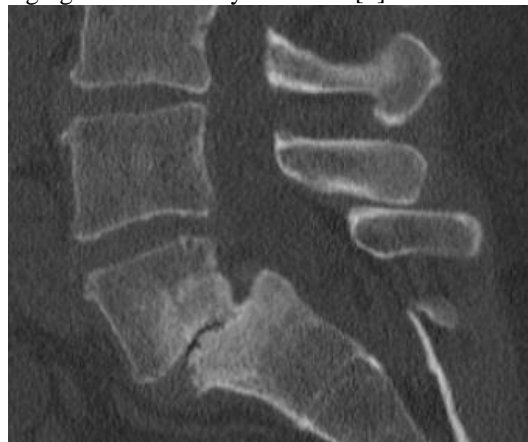conservative management to advanced spinal surgery. Proper recognition of transitional vertebrae, ligament attachments, and disc herniation characteristics ensures safe and effective patient care [5].

#### Plain Films-Imaging Modalities

Evaluation of the lumbar spine relies on multiple imaging modalities, each selected according to the suspected pathology, radiation exposure, patient-specific contraindications, and potential allergies to contrast agents. The American College of Radiology (ACR) provides evidence-based appropriateness criteria to guide the choice of imaging in various clinical scenarios, including acute trauma, nonspecific low back pain, and back pain accompanied by fever or neurological deficits [4][6]. These criteria emphasize the need for a tailored approach, balancing diagnostic yield with patient safety and resource utilization. Plain radiography remains the most accessible and widely used initial imaging modality for lumbar spine assessment. Radiographs are cost-effective, portable, and capable of rapidly providing critical structural information. They are particularly effective for evaluating vertebral body alignment, gross fractures, dislocations, and assessing spinal stability through dynamic flexion and extension views. Radiographs can detect major degenerative changes and guide initial clinical management. Despite these advantages, radiographs have inherent limitations. Nondisplaced fractures, early metastatic lesions, and subtle soft tissue abnormalities may be obscured by overlying anatomical structures, bowel gas, or implanted hardware. Positioning challenges can further compromise image quality. Additionally, the cumulative radiation exposure, though low compared to computed tomography, is a consideration, particularly in pregnant patients, necessitating judicious use [6].

Plain films remain an indispensable first-line tool due to their accessibility and diagnostic efficiency in identifying gross structural abnormalities. Their utility is enhanced when combined with patient history, physical examination, and consideration of red flag symptoms. In scenarios where radiographs are insufficient to fully characterize pathology, cross-sectional imaging such as computed tomography or magnetic resonance imaging is warranted. CT provides high-resolution evaluation of osseous structures and complex fractures, while MRI offers superior soft tissue and neural visualization, including intervertebral discs, spinal cord, and nerve roots. The integration of these modalities according to ACR recommendations ensures comprehensive and safe evaluation of lumbar spine pathology, supporting accurate diagnosis and informed clinical decision-making. Effective use of plain radiographs requires awareness of their strengths and limitations, careful patient positioning, and selective application guided by clinical

indications. This approach maximizes diagnostic yield while minimizing unnecessary radiation exposure and facilitates timely escalation to advanced imaging when clinically indicated [6].



**Fig. 2:** Grade II Spondylolisthesis. Lumbar spine sagittal CT of L5-S1 revealing grade II spondylolisthesis.

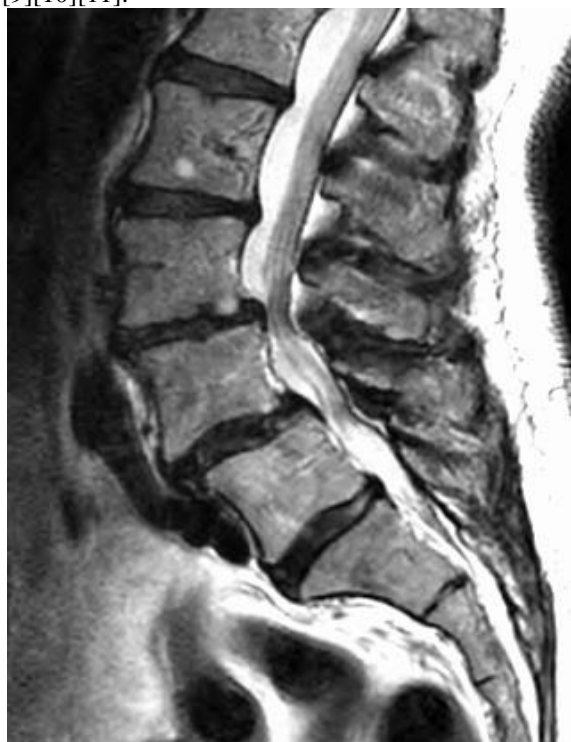#### Computed Tomography

Computed tomography (CT) represents a highly reliable modality for detailed evaluation of the lumbar spine, particularly in assessing osseous structures. It provides superior bony resolution, making it invaluable for identifying trauma, nondisplaced and complex fractures, scoliosis, and preoperative and postoperative changes (see Image. Grade II Spondylolisthesis, CT). CT is especially useful after spinal surgery, as it allows evaluation of surgical hardware and bone grafts, which may not be clearly visualized on MRI. In patients with implanted spinal devices or contraindications to MRI, CT myelography offers an alternative method of spinal canal evaluation. This technique involves the injection of a radiopaque contrast agent into the subarachnoid space via lumbar puncture, performed under fluoroscopic or CT guidance [7]. CT myelography is also essential in detecting occult cerebrospinal fluid leaks following surgery or traumatic injury to the lumbar spine [8]. Contraindications include pregnancy and general lumbar puncture contraindications such as severe coagulopathy or elevated intracranial pressure. Overall, CT provides rapid, high-resolution imaging that is critical for surgical planning and evaluation of complex spinal pathology.

#### Magnetic Resonance

Magnetic resonance imaging (MRI) is recognized as one of the most sensitive and specific modalities for evaluating lumbar spine pathology. Unlike CT, MRI does not involve ionizing radiation, allowing repeated imaging without associated radiation risks (see Image. Magnetic Resonance Imaging, Lumbar). MRI provides comprehensive visualization of vertebral bodies, intervertebral discs, spinal canal, meninges, spinal cord, conus medullaris, cauda equina, and exiting nerve roots. Multiple

sequences in axial and sagittal planes, including T1, T2, and STIR (short tau inversion recovery), allow detailed assessment of varied pathological processes (see Image. Lumbar Disc Degeneration, Multiple Levels; Sagittal MRI of Lumbar Spine With Spondylolisthesis, L3-4 and L4-5). Post-contrast T1 sequences enhance detection of spinal infections, postoperative changes, vascular malformations, primary tumors, and metastases. MRI is particularly effective in evaluating metastatic disease in the lumbar spine, including prostate cancer involvement, and identifying complications such as spinal cord compression. STIR sequences are highly sensitive to marrow edema, revealing areas of increased signal associated with trauma, infection, or malignancy [9][10][11].



**Fig. 3:** Sagittal MRI of Lumbar Spine With Spondylolisthesis, L3-4 and L4-5.

#### Ultrasonography

Ultrasonography serves a specialized role in lumbar spine evaluation, particularly in neonates. Bedside imaging can assess congenital anomalies, detect spinal cord abnormalities, and visualize cerebrospinal fluid pulsations. In adult patients, ultrasonography assists in evaluating superficial collections and guiding percutaneous interventions.

#### Nuclear Medicine

Nuclear medicine provides functional assessment of bone and spinal pathology. Bone scintigraphy using technetium-99m methylene diphosphonate highlights areas of active bone turnover, such as osteoblastic metastases from prostate cancer, though fractures can result in false positives. F-18 FDG PET/CT enables localization of hypermetabolic lesions by combining PET functional

data with CT anatomical imaging, aiding in the evaluation of bony metastases and spinal cord masses. FDG uptake may also indicate infection, such as vertebral osteomyelitis, due to altered glucose metabolism at the site of inflammation. A newer modality, 18F-NaF PET/CT, provides higher-quality imaging for osseous metastases compared to traditional bone scans [12].

#### Angiography

Angiography is utilized for both diagnostic and therapeutic purposes in lumbar spine vascular pathology. It identifies and guides treatment of arteriovenous malformations, dural fistulas, and arterial pseudoaneurysms following trauma. Preoperative embolization of hypervascular bone tumors is performed to reduce intraoperative blood loss. Angiography remains a critical adjunct in complex vascular and traumatic conditions of the lumbar spine.

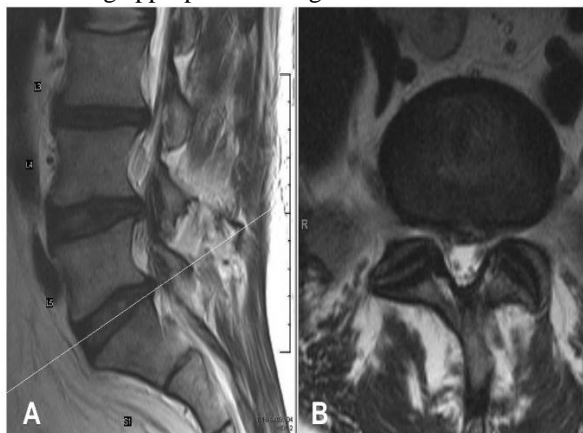
#### Clinical Significance

Lumbar spine pathologies encompass a wide spectrum of disorders, which can be classified anatomically into lesions affecting the bony structures, intervertebral discs, meninges, spinal cord, or paraspinal regions. Selection of the appropriate imaging modality is critical to accurately characterize these lesions, guiding diagnosis, treatment planning, and prognosis. Imaging choice depends on the suspected etiology, which may include trauma, congenital anomalies, degenerative changes, infection, vascular abnormalities, or neoplastic processes. Early and precise identification of pathology is essential to prevent complications, optimize patient outcomes, and facilitate targeted interventions.

#### Degenerative Disc Disease

Degenerative disc disease (DJD) represents the most common cause of low back pain, with prevalence increasing with age. Contributing factors include mechanical stress, microtrauma, and occupational or lifestyle-related strain. On MRI, a healthy intervertebral disc demonstrates hyperintense signal on T2-weighted sequences, reflecting normal hydration and disc integrity. Age-related degeneration results in decreased T2 signal intensity, loss of disc height, and structural irregularities. Endplate changes, collectively termed Modic changes, are frequently associated with degenerative discs and are classified into three types [13][14]. Modic type I changes exhibit linear edema along the endplates, appearing hypointense on T1 and hyperintense on T2 sequences, indicating acute inflammatory changes. Modic type II changes demonstrate fatty replacement of the marrow, hyperintense on both T1 and T2 sequences. Modic type III changes correspond to sclerotic endplate alterations, hypointense on T1 and T2 sequences. Degenerative changes in combination with facet joint arthropathy may result in spinal stenosis, which can further compromise neural elements. Spinal stenosis

may also arise from congenital narrowing, traumatic fractures, epidural masses, or excessive epidural fat deposition, such as epidural lipomatosis. Accurate imaging enables differentiation of these etiologies, facilitating appropriate management.



**Fig. 4:** Lumbar Disc Degeneration, Multiple Levels.

#### **Discitis and Osteomyelitis**

Discitis and vertebral osteomyelitis constitute infectious processes of the intervertebral disc and adjacent vertebral bodies. Hematogenous dissemination is the predominant mechanism, although postoperative complications and trauma may also precipitate infection. Clinically, affected patients often present with prolonged low back pain accompanied by systemic symptoms such as fever. MRI is the modality of choice for diagnosis, providing high-resolution visualization of disc signal alterations, marrow edema, and endplate irregularities. Post-contrast sequences delineate the extent of disc involvement, including potential spread into adjacent vertebral bodies, paraspinal soft tissues, and the spinal canal. MRI can further define the degree of epidural, intradural, or leptomeningeal extension, guiding surgical or interventional planning. CT, including three-dimensional reconstructions, is valuable for preoperative evaluation, particularly in cases requiring hardware placement. Percutaneous drainage of paraspinal abscesses can be guided by CT or ultrasonography. In cases of occult infection, white blood cell-tagged nuclear medicine imaging may provide additional diagnostic clarity, identifying metabolically active infectious foci that are otherwise radiographically occult. Comprehensive understanding of lumbar spine pathologies and their imaging characteristics is essential for clinicians and radiologists. Accurate differentiation of degenerative, infectious, and other structural abnormalities enables targeted treatment, reduces morbidity, and informs long-term management strategies. Imaging plays a central role not only in diagnosis but also in monitoring progression, evaluating therapeutic response, and guiding surgical or minimally invasive interventions [14].

#### **Spinal Canal Masses**

Spinal canal masses can be anatomically classified based on their location relative to the spinal cord and meninges into three main categories: intramedullary, extramedullary-intradural, and extradural lesions. Accurate localization is crucial for diagnosis, management, and surgical planning. Magnetic resonance imaging (MRI) with contrast remains the modality of choice for evaluating these masses, providing detailed visualization of both neural and soft tissue structures and allowing characterization of lesion morphology, extent, and involvement of adjacent structures [14].

#### **Intramedullary Masses**

Intramedullary lesions arise within the substance of the spinal cord itself. Common pathologies in this category include tumefactive demyelination, primary spinal cord tumors, and vascular malformations. Tumors often result in expansion of the spinal cord, associated edema, hemorrhagic components, and contrast enhancement on MRI. Intramedullary neoplasms such as ependymomas and astrocytomas demonstrate specific enhancement patterns and may extend over multiple spinal levels. Tumefactive demyelination can present as a mass-like lesion with cord swelling and signal alteration similar to neoplasms; however, these lesions typically regress following appropriate medical therapy, distinguishing them from true neoplastic masses. Vascular malformations, including intramedullary arteriovenous malformations (AVMs), may manifest with serpiginous flow voids, signal abnormalities from prior subarachnoid hemorrhage, or prominent intramedullary vessels. Three-dimensional MR sequences and spinal MR angiography assist in precise localization and preoperative planning, while conventional catheter angiography remains the gold standard for definitive evaluation of AVM origin, feeding vessels, and dural fistulas [14].

#### **Extramedullary-Intradural Masses**

Extramedullary-intradural lesions occupy the space outside the spinal cord but remain within the dural sac. This category commonly includes meningiomas, schwannomas, intradural lipomas, epidermoid tumors, arachnoid cysts, and metastatic lesions. On axial MRI, these masses typically cause widening of the subarachnoid space with displacement of the spinal cord, often resulting in cord compression. Most extramedullary-intradural lesions exhibit characteristic imaging features: meningiomas are usually iso- to hypointense on T1-weighted images and show homogeneous enhancement after contrast, whereas schwannomas may present with cystic degeneration or heterogeneous enhancement. Intradural lipomas demonstrate hyperintense signal on T1-weighted sequences due to fatty content, and arachnoid cysts are generally hypointense on T1 and hyperintense on T2-weighted sequences, without contrast

enhancement. Metastatic deposits in the intradural compartment are less common but can be identified by their irregular margins and enhancement patterns. Accurate identification of lesion type aids in planning surgical resection or targeted radiation therapy [12][13].

### **Extradural Masses**

Extradural lesions are located outside the dural sac and may involve the epidural space, vertebral bodies, or surrounding soft tissues. Common extradural pathologies include epidural abscesses, epidural hematomas, metastatic involvement of vertebral bodies, and epidural lipomatosis. These lesions often lift the dura off the adjacent vertebral lamina or body, producing compression of the dural sac and neural elements. Multiplanar MRI sequences, particularly sagittal and axial T1 and T2 images with contrast, are essential for delineating lesion extent, involvement of the vertebral column, and mass effect on the spinal cord and nerve roots. Extradural abscesses and hematomas represent acute neurosurgical emergencies, whereas metastatic lesions require evaluation for systemic disease burden. Epidural lipomatosis, often associated with chronic corticosteroid use or obesity, is best characterized by fatty signal intensity on T1-weighted sequences. Comprehensive imaging of spinal canal masses is fundamental for differential diagnosis, surgical planning, and treatment stratification. MRI provides superior soft tissue contrast, multiplanar visualization, and the ability to characterize enhancement patterns, making it the cornerstone of evaluation. Ancillary techniques such as MR angiography, CT, and conventional catheter angiography complement MRI in vascular lesions and preoperative assessment, ensuring precise localization, accurate diagnosis, and safe intervention [12].

### **Trauma**

Trauma to the thoracolumbar spine represents a significant cause of morbidity and requires systematic evaluation to guide management. Comprehensive classification systems have been developed to categorize vertebral fractures and inform treatment strategies. Traditional approaches often rely on the concept of spinal columns to assess fracture stability. The three-column model, widely adopted in clinical practice, divides the spine into anterior, middle, and posterior segments. The anterior column includes the anterior longitudinal ligament and the anterior half of the vertebral body. The middle column comprises the posterior half of the vertebral body along with the posterior longitudinal ligament. The posterior column encompasses the supraspinous and interspinous ligaments, ligamentum flavum, and facet joints. Fractures that involve two or more columns are considered unstable and typically necessitate surgical intervention or close monitoring to prevent further neurological compromise. Computed tomography (CT) is the preferred imaging

modality in acute spinal trauma due to its high spatial resolution and ability to precisely delineate bony structures. CT allows detailed evaluation of fracture morphology, fragment displacement, comminution, and involvement of the vertebral canal. It is particularly useful in complex fractures, burst fractures, and injuries requiring preoperative planning. MRI complements CT by providing critical information on soft tissue and neural structures. In the context of trauma, MRI can identify ligamentous injuries, epidural or subarachnoid hemorrhage, spinal cord compression, contusions, and transections. The presence of neurological deficits mandates prompt MRI evaluation to assess the extent of cord involvement, guide surgical decision-making, and predict functional outcomes [15].

Assessment of trauma extends beyond the osseous and neural elements of the spine. Lumbar spine fractures, particularly transverse fractures, are frequently associated with visceral injuries. Approximately 51% of patients with transverse fractures exhibit concomitant damage to abdominal or retroperitoneal organs, including the peritoneum, kidneys, and vascular structures [15]. Early recognition of these associated injuries is essential, as delayed diagnosis can result in significant morbidity or mortality. Multiplanar CT imaging of the abdomen and pelvis is often performed concurrently in high-energy trauma to screen for visceral injury. Treatment decisions in thoracolumbar trauma are informed by fracture stability, neurological status, and associated injuries. Stable, isolated fractures without neurological compromise may be managed conservatively with immobilization and close follow-up. Unstable fractures, fractures with significant canal compromise, or those associated with progressive neurological deficits frequently require surgical intervention. Surgical planning relies heavily on the combined information from CT and MRI, including the integrity of spinal columns, canal compromise, and soft tissue injury. In conclusion, trauma to the thoracolumbar spine demands a multidisciplinary approach combining precise imaging, clinical assessment, and systematic classification. CT provides detailed osseous evaluation, while MRI elucidates ligamentous, neural, and hemorrhagic injuries. Recognition of associated visceral trauma is critical, particularly in transverse fractures, to optimize patient outcomes. Integration of imaging findings with clinical presentation and classification systems allows tailored treatment, reduces the risk of long-term disability, and guides both conservative and surgical management strategies [15].

### **Postoperative Lumbar Spine Imaging**

The increasing frequency of spinal surgeries has led to a parallel rise in the need for imaging to assess postoperative complications. Postoperative evaluation is essential to identify early and late complications that may affect patient outcomes,

guide further treatment, and prevent long-term morbidity. Early complications typically manifest within days to weeks after surgery and include hardware malpositioning, hematoma formation, infection, and cerebrospinal fluid (CSF) leakage. Identification of these complications is crucial, as delayed recognition can result in neurological compromise, persistent pain, or systemic infection. Hardware malposition is a common early complication, particularly in patients undergoing instrumentation with screws, rods, or interbody devices. CT is the preferred imaging modality for evaluating the precise position of implants and detecting any malalignment or migration. Hematomas, which may exert mass effect on the neural elements, are best evaluated using MRI due to its superior soft tissue contrast. In cases of suspected infection or CSF leakage, contrast-enhanced MRI can delineate the extent of fluid collections, characterize abscesses, and detect dural defects. Early postoperative imaging allows targeted interventions such as surgical revision, drainage, or antibiotic therapy [16].

Late postoperative complications may present weeks to years after surgery and include recurrent disc herniation, non-union or hardware failure, epidural fibrosis, arachnoiditis, and chronic infections such as discitis, osteomyelitis, or paraspinal and epidural abscesses [16]. Recurrent disc herniation must be distinguished from granulation tissue or postoperative scar. On MRI, recurrent disc material generally demonstrates less avid enhancement compared with granulation tissue, which typically shows homogeneous or intense enhancement. A rim-enhancing pattern may indicate herniated disc fragments. MRI is particularly useful for evaluating epidural fibrosis and arachnoiditis, which are challenging to detect on CT. Epidural fibrosis appears as low-signal-intensity tissue on T1-weighted sequences with variable enhancement, often enveloping the dural sac and nerve roots. Arachnoiditis can manifest as clumping of nerve roots, obliteration of the subarachnoid space, or abnormal enhancement, findings that are best appreciated on high-resolution MRI sequences. CT remains invaluable in assessing osseous complications such as non-fusion, screw loosening, and hardware fracture. Multiplanar reconstructions improve visualization of interbody cages, pedicle screws, and alignment, aiding surgical planning when revision is necessary. Nuclear medicine studies, including tagged white blood cell scans or FDG-PET/CT, may be adjunctively employed to evaluate chronic or occult infection, particularly in cases where MRI findings are equivocal. Overall, postoperative lumbar spine imaging requires a multimodal approach. CT and MRI are complementary, with CT providing superior evaluation of bony structures and instrumentation,

and MRI offering high sensitivity for soft tissue and neural complications. Proper selection of imaging modality based on clinical suspicion, timing of symptoms, and surgical history enhances diagnostic accuracy, facilitates timely intervention, and reduces unnecessary healthcare expenditures. Integration of imaging findings with clinical evaluation ensures optimal patient management, supports evidence-based decision-making, and improves long-term outcomes in patients undergoing lumbar spine surgery [16].

#### **Conclusion:**

Advanced imaging plays a pivotal role in the evaluation and management of lumbar spine disorders, supporting accurate diagnosis across a wide spectrum of pathological conditions. The lumbar spine is anatomically complex and subject to degenerative, infectious, neoplastic, traumatic, and postoperative changes, all of which require careful imaging selection guided by clinical context. No single imaging modality is sufficient for all scenarios; rather, optimal diagnostic accuracy is achieved through the judicious integration of complementary techniques. Plain radiographs remain valuable as an accessible first-line investigation for structural assessment, while CT excels in evaluating bony anatomy, fractures, and postoperative instrumentation. MRI stands as the cornerstone of lumbar spine imaging due to its superior visualization of intervertebral discs, neural elements, spinal canal contents, and soft tissue pathology, without exposure to ionizing radiation. Adjunctive modalities, including nuclear medicine studies and angiography, provide critical functional and vascular information in select cases. Adherence to evidence-based guidelines, such as the ACR appropriateness criteria, ensures efficient resource utilization while minimizing patient risk. Ultimately, a thorough understanding of lumbar spine anatomy, pathology, and imaging characteristics enables radiologists and clinicians to make informed decisions, guide targeted interventions, and improve patient outcomes. Continued advancements in imaging technology will further enhance diagnostic precision and clinical care in lumbar spine disorders.

#### **References:**

1. Chou R, Deyo RA, Jarvik JG. Appropriate use of lumbar imaging for evaluation of low back pain. *Radiologic clinics of North America*. 2012 Jul;50(4):569-85. doi: 10.1016/j.rcl.2012.04.005.
2. Edwards J, Hayden J, Asbridge M, Gregoire B, Magee K. Prevalence of low back pain in emergency settings: a systematic review and meta-analysis. *BMC musculoskeletal disorders*. 2017 Apr 4;18(1):143. doi: 10.1186/s12891-017-1511-7.
3. Farshad-Amacker NA, Farshad M, Winklehner A, Andreisek G. MR imaging of

- degenerative disc disease. *European journal of radiology*. 2015 Sep;84(9):1768-76. doi: 10.1016/j.ejrad.2015.04.002.
4. Patel ND, Broderick DF, Burns J, Deshmukh TK, Fries IB, Harvey HB, Holly L, Hunt CH, Jagadeesan BD, Kennedy TA, O'Toole JE, Perlmutter JS, Policeni B, Rosenow JM, Schroeder JW, Whitehead MT, Cornelius RS, Corey AS. ACR Appropriateness Criteria Low Back Pain. *Journal of the American College of Radiology : JACR*. 2016 Sep;13(9):1069-78. doi: 10.1016/j.jacr.2016.06.008.
  5. Fardon DF, Williams AL, Dohring EJ, Murtagh FR, Gabriel Rothman SL, Sze GK. Lumbar disc nomenclature: version 2.0: Recommendations of the combined task forces of the North American Spine Society, the American Society of Spine Radiology and the American Society of Neuroradiology. *The spine journal : official journal of the North American Spine Society*. 2014 Nov 1;14(11):2525-45. doi: 10.1016/j.spinee.2014.04.022.
  6. Daffner RH, Hackney DB. ACR Appropriateness Criteria on suspected spine trauma. *Journal of the American College of Radiology : JACR*. 2007 Nov;4(11):762-75
  7. Pomerantz SR. Myelography: modern technique and indications. *Handbook of clinical neurology*. 2016;135():193-208. doi: 10.1016/B978-0-444-53485-9.00010-6.
  8. Malhotra A, Kalra VB, Wu X, Grant R, Bronen RA, Abbed KM. Imaging of lumbar spinal surgery complications. *Insights into imaging*. 2015 Dec;6(6):579-90. doi: 10.1007/s13244-015-0435-8.
  9. Pizones J, Izquierdo E, Alvarez P, Sánchez-Mariscal F, Zúñiga L, Chimeno P, Benza E, Castillo E. Impact of magnetic resonance imaging on decision making for thoracolumbar traumatic fracture diagnosis and treatment. *European spine journal : official publication of the European Spine Society, the European Spinal Deformity Society, and the European Section of the Cervical Spine Research Society*. 2011 Aug;20 Suppl 3(Suppl 3):390-6. doi: 10.1007/s00586-011-1913-4.
  10. Kumar Y, Hayashi D. Role of magnetic resonance imaging in acute spinal trauma: a pictorial review. *BMC musculoskeletal disorders*. 2016 Jul 22;17():310. doi: 10.1186/s12891-016-1169-6.
  11. Willson MC, Ross JS. Postoperative spine complications. *Neuroimaging clinics of North America*. 2014 May;24(2):305-26. doi: 10.1016/j.nic.2014.01.002.
  12. Iagaru A, Young P, Mittra E, Dick DW, Herfkens R, Gambhir SS. Pilot prospective evaluation of 99mTc-MDP scintigraphy, 18F NaF PET/CT, 18F FDG PET/CT and whole-body MRI for detection of skeletal metastases. *Clinical nuclear medicine*. 2013 Jul;38(7):e290-6. doi: 10.1097/RLU.0b013e3182815f64.
  13. Dudli S, Fields AJ, Samartzis D, Karppinen J, Lotz JC. Pathobiology of Modic changes. *European spine journal : official publication of the European Spine Society, the European Spinal Deformity Society, and the European Section of the Cervical Spine Research Society*. 2016 Nov;25(11):3723-3734
  14. Modic MT, Steinberg PM, Ross JS, Masaryk TJ, Carter JR. Degenerative disk disease: assessment of changes in vertebral body marrow with MR imaging. *Radiology*. 1988 Jan;166(1 Pt 1):193-9
  15. Patten RM, Gunberg SR, Brandenburger DK. Frequency and importance of transverse process fractures in the lumbar vertebrae at helical abdominal CT in patients with trauma. *Radiology*. 2000 Jun;215(3):831-4
  16. Herrera Herrera I, Moreno de la Presa R, González Gutiérrez R, Bárcena Ruiz E, García Benassi JM. Evaluation of the postoperative lumbar spine. *Radiologia*. 2013 Jan-Feb;55(1):12-23. doi: 10.1016/j.rx.2011.12.004.